

Diagnosis & Treatment Planning

Treatment Planning for Predictability

by Glenn DuPont, DDS

The goal of any dental professional is to help people achieve dental health and well-being in a comfortable environment. Treatment planning is only one facet of dental service, and it begins with a philosophy of what is best and most conservative for the patient. This philosophy is the core of complete dentistry. Complete dentistry requires good communication with patients to blend what each patient desires with what each patient needs for total masticatory system health.

It can become too easy to treatment plan what is best for the dentist and not for the patient, especially when dentists have the ability to create beautiful esthetics.¹ Humans have no provision for regeneration, and the hardness of enamel suggests that teeth should last a lifetime. Therefore, creating stability of the complete masticatory system is critical for predictable long-term results.

To achieve this result, dentists must consider all parts of the masticatory system when evaluating patients. The health and stability of the temporomandibular joints (TMJs), the supporting musculature, the periodontium, and the teeth must be evaluated carefully on every new patient (Figure 1 [View Figure](#)). This article outlines the examination process, occlusal requirements, and analysis procedure used in complete dentistry, then describes how to turn this information into a treatment plan.

The Examination Process

From the author's 29 years in practice, a process of seven essential steps has been developed to ensure that the treatment plan will lead to masticatory system health.

1. Patient interview
2. TMJ screening; history and clinical examination
3. Soft-tissue examination
4. Occlusal evaluation
5. Teeth examination
6. Supporting structures examination
7. Photographs and radiographs

After the examination is completed, a crucial eighth step is to communicate the findings to the patient in a manner he or she will understand. Remember, patients cannot perceive a need for treatment if they do not understand clearly the problems and the implications of those problems if left untreated. Do not attempt to explain treatment options until both the problems and the implications are understood.

The Requirements of Occlusal Stability

Dawson described five requirements for occlusal stability.²

1. Stable stops on all teeth of equal intensity when the condyles are in centric relation (CR)

2. Anterior guidance in harmony with the border movements of the envelope of function
3. Disclusion of all posterior teeth in protrusive movements
4. Disclusion of all posterior teeth on the nonworking (balancing) side
5. Disclusion or noninterference of all posterior teeth on the working side, with either the lateral anterior guidance or the border movements of the condyle

In establishing a stable occlusion, anterior guidance assumes the key role. The anterior teeth are better able to resist lateral stress than the posterior teeth because of their mechanical position in relation to the TMJ fulcrum and the muscle force.

Assessing Worn Dentition

The worn dentition, especially worn anterior teeth, presents a great challenge. In these cases, the goal is to create atraumatic, comfortable, stable occlusion and still be able to achieve optimal esthetics. The author's 29 years of experience treating patients with worn dentition has resulted in some important observations.

- It is very helpful to adhere to the rules of programmed treatment planning precisely, applying each step in sequence.
- Worn teeth may (or may not) have deflective interferences.
- Wear usually does not cause a loss of vertical dimension of occlusion (VDO). The VDO usually can be slightly increased with comfort and stability.
- Posterior teeth cannot wear from attrition in an ideal occlusion. Therefore, treatment must involve a stable, repeatable, CR starting point combined with anterior guidance in harmony with the posterior disclusion in every excursion. Do not steepen or restrict the envelope of function. A shallow envelope of function seems to provide a lessening of muscle activity and a more stable result. The disclusion provided by the envelope of function needs to be combined with a shallow curve of Spee and curve of Wilson to provide posterior disclusion. Attritional wear occurs when the teeth are in the way of function.
- Test everything out in provisionals.

Analysis with Mounted Diagnostic Casts

The planning for definitive occlusion and esthetics begins at the diagnostic wax-up stage. Mounted casts and articulators should be used to minimize errors in basic geometric principles. For example, if the occlusion is opened on one axis and then closed on another axis, it will not return to the same position.

Working out ideal function and esthetics on study casts can provide great value. Study casts allow for clear patient communication as well as communication with specialists. They help in efficient sequencing of treatment for predictability, profitability, and especially confidence during the consultation with the patient.

Treatment Planning Model and Photographic Flow Sheet

Step 1: Choose Condylar Position

Based on the TMJ screening and occlusal evaluation, choose a condylar position: maximum intercuspation (MI), CR, or treatment position. If the case is an MI case, the models should be mounted in MI; if a CR case, the models should be mounted in CR; and if a treatment position is used, the models should be mounted for final study in that position.

Step 2: Go Tooth by Tooth

Using the data from the casts, soft- and hard-tissue examinations, supporting structures examination, and the photographs, mark the hopeless teeth, the questionable teeth, and the teeth that need to be restored (crowned or onlaid) because of weakness or breakdown. At the Dawson Academy, a specific series of photographs are recommended to help in the esthetic and functional evaluation as well as patient acceptance (see Pace).

Step 3: Evaluate Maxillary-Mandibular Occlusal Plane, Facial Asymmetries, and Skeletal Abnormalities

Using photographs (full-face, profile, and smile views) and mounted casts, envision the result functionally and esthetically.

Step 4: Choose Vertical and Horizontal Position of Mandibular Incisal Edge

Using the casts and photographs (rest, "E" position, smile from three views, full-face, profile smile, tipped up anterior occlusion view and tipped-down smile) as references, wax or reposition the teeth into an ideal position. Then, confirm that an acceptable ideal position has been accomplished.

Step 5: Choose Vertical and Horizontal Position of Maxillary Incisal Edge

Using the photographs (rest, "E" position, smile from three views, full-face, profile smile, and tipped-down smile), wax or reposition the teeth into an ideal position. Again, confirm that an acceptable ideal position has been accomplished. This is a key step when cosmetic concerns are driving the case.

Step 6: Choose VDO

After the working VDO is decided, choose a method of equilibration: reductive equilibration (balance casts back to original vertical dimension by removal of interferences) or additive equilibration (add to posterior teeth as a restorative or orthodontic process) or a combination of both. This will help to provide an anterior guidance that is as shallow as possible and still provide posterior disclusion and the desired esthetics. Remember, lengthening anterior teeth often will steepen the guidance and infringe on the envelope of function. Look for evidence of horizontal parafunction (anterior wear or mobility) on clinical analysis, photographs, and casts that will indicate that the changes made are not being accepted by that patient's system.

Step 7: Provide Equal-Intensity Stops

If reductive equilibration is the choice, balance all premature interfering contacts to return the pin to contact with the anterior guide table and to establish uniform centric stops all the way around the arch, including the anterior teeth. If additive equilibration is the choice, wax the posterior teeth (one or both arches) to provide uniform anterior and posterior stops.

At this point, the case should have uniform centric stops with a good cusp-fossa relationship on each posterior tooth and a stable holding contact on each anterior tooth. If not, consider sawing and moving the tooth, or waxing to restore the teeth. Be sure to create ideal lower anterior incisal edge position (Step 4), as well as ideal maxillary lingual contour through shaping or waxing.

Step 8: Eliminate Balancing and Working Interferences

First, mark the balancing and working interferences with a red ribbon by unlocking

the CR lock and guiding the cast in left, right, and protrusive excursions. Then, lock the cast back in CR, marking the centric stops with a black ribbon. Next, eliminate all the red skid marks that are not superimposed directly over the black centric stops which should be established on all posterior teeth. Finally, what remains should be the centric stops on the posterior teeth and red guiding marks on the anterior teeth (lines on the front, dots in the back).

Step 9: Harmonize Anterior Guidance

Harmonize the anterior guidance to establish smooth, gliding left, right, and protrusive movements of the casts. It is desirable to share this movement with as many anterior teeth as possible.

Consider waxing the teeth to create an ideal anterior guidance, being careful not to constrict (steepen) the envelope of function (Figure 2 [View Figure](#)). The anterior teeth should be in harmony with the functional matrix created by the lips, the tongue, and the envelope of function.

Step 10: Final Functional and Esthetic Check

After the anterior guidance has been harmonized, recheck for any balancing, working, or protrusive interferences and eliminate them. Create smooth anterior movements.

Try to visualize the final result and decide, through model work and photographic analysis, if it would be completed most successfully through equilibration, tooth repositioning (orthodontics), restorative dentistry, or orthognathic surgery. Regardless of the treatment option, the goal is always to do the least amount of dentistry to provide the patient with the requirements of occlusal stability and satisfy the elective esthetic desires of the patient.

Treatment Sequencing

When treatment sequencing for efficiency, predictability, and profitability, the treatments can be organized into phases.

Phase I Treatment

- Eliminate pain and/or abscesses, using splint therapy where applicable
- Address emergency concerns of patient
- Initial scaling and root planing if needed
- Provide home-care instructions if needed
- Implement caries-control treatments if needed
- Refer to specialists for evaluation to get the “whole picture”
- Second consultation if needed

Phase II Treatment

- Splint therapy for treatment position
- Equilibration
- Referral to specialists for treatment (orthodontist, oral surgeon, periodontist, endodontist)
- Provisional restorations

Re-evaluate to be sure TMJ, periodontal, orthodontic, or other work is completed satisfactorily. Discuss any final esthetic considerations with the patient. Using the above 10 steps, re-evaluate to ensure the provisionals are approved by the dentist

and the patient.

Phase III Treatment

Phase III is the restorative phase. It is ideal to finish in the order below. This order allows for the easiest way to ensure predictability, especially as it relates to communication with the laboratory. It also allows for reassessment of function, ideal cusp design, and the necessary room for restorations at each step.

1. Mandibular anteriors
2. Maxillary anteriors
3. Mandibular posteriors
4. Maxillary posteriors

Case Example

These principles were used in the treatment of a patient with severe wear and an anterior deep overbite (Figure 3 [View Figure](#) and Figure 4 [View Figure](#)). The TMJs were stable and, to treat very conservatively, the author treated the patient at her existing VDO. The most important step in any treatment is to work out every detail on the study casts (Figure 5 [View Figure](#)). The diagnostic wax-up then is used for discussion with the patient, creation of preparation guides (Figure 6 [View Figure](#)), and communication with any specialists, in this case the periodontist. Therefore, equilibration was used to provide equal intensity centric stops on the posterior teeth. Periodontal treatment by Dr. Ron Kobernick was used to level the gingival height and remove the maxillary buccal exostosis (Figure 7 [View Figure](#)). The anterior teeth then were restored with all-ceramic restorations (Rick Sontag, CDT, Center Dental Lab), providing definitive centric stops and opening the envelope of function. The patient's deep overbite and incisal edge positions were maintained to fit her functional matrix (Figure 8 [View Figure](#) and Figure 9 [View Figure](#)). Therefore, predictability, stability, and ideal esthetics were developed to satisfy her needs.

Conclusion

A comprehensive examination that includes every aspect of the stomatognathic system combined with the application of the information gathered into a conservative treatment plan represents the most important and critical components in creating a predictable, functional, and esthetic result with long-lasting stability. Following the specific steps outlined can help clinicians achieve these results predictability, efficiently, and profitably in any type of restorative case.

References

1. Miller L. Symbiosis of esthetics and occlusion: thoughts and opinions of a master of esthetic dentistry, *J Esthet Dent*. 1999;11(3):155-165.
2. Peter E. Dawson, *Functional Occlusion From TMJ to Smile Design*. St. Louis, MO: Mosby Elsevier; 2006.

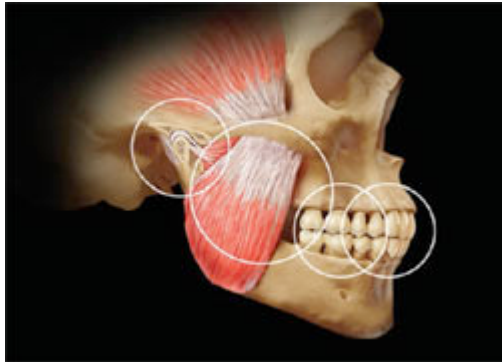


FIGURE 1 The key components of the masticatory system: TMJs, supporting musculature, periodontia, and teeth.

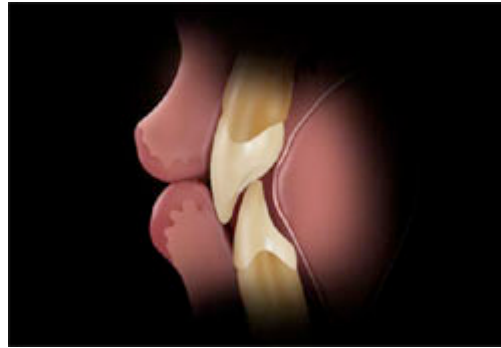


FIGURE 2 Ideal anterior guidance. Note that the anterior teeth are in harmony with the functional matrix created by the lips, the tongue, and the envelope of function.

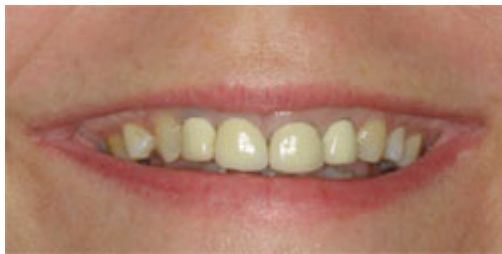

FIGURE 3 Preoperative smile view.



FIGURE 4 Preoperative full-face view.

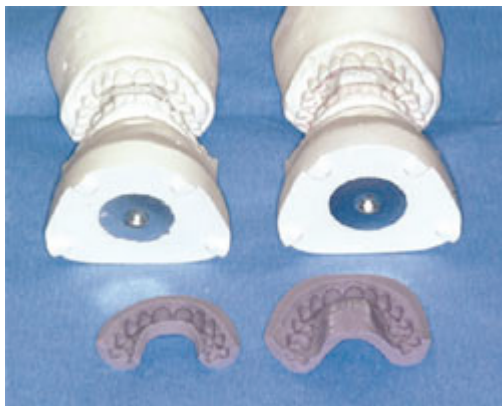


FIGURE 5 The diagnostic casts.

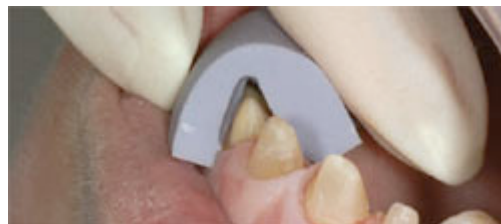

FIGURE 6 The preparation matrix.

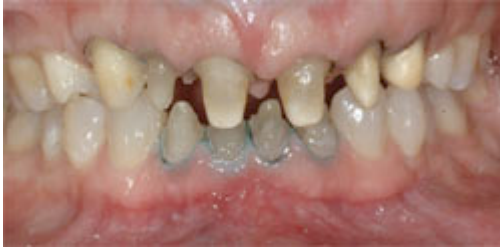

FIGURE 7 The final preparations.

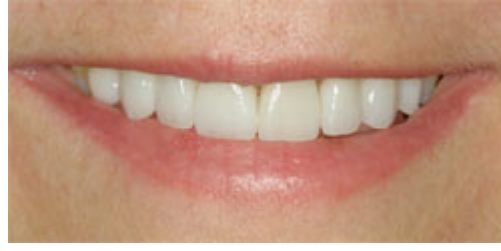

FIGURE 8 The final preparations.



FIGURE 9 Postoperative full-face view.

About the Author

Glenn DuPont, DDS
Private Practice
St. Petersburg, Florida

[Print article](#)